

The Utility Value Of Ultrasound As An Investigative Tool In Colloid And Malignant Thyroid Disorders

¹Olatunji A. A., ²Abdulrahman A., ³Inikori A. K., ³Ibrahim M. S., and ³Abdulkadir A. Y.

¹Department of Radiology, Olabisi Onabanjo University Teaching Hospital, Sagamu, Ogun State.

²Department of Surgery University of Ilorin Teaching Hospital, Ilorin, Kwara State

³Department of Radiology, University of Ilorin Teaching Hospital, Ilorin, Kwara State

Abstract.

Although the diagnosis of cancer can only be confirmed by histology, other diagnostic modalities such as ultrasonography, which is cheap and readily available, can be used as alternatives particularly where histology is not readily available.

This study was carried out to assess the usefulness or otherwise, of some ultrasonographic appearances in predicting certain thyroid pathologies including cancer.

Ultrasound of thyroid masses was carried out with appropriate positioning in patients with neck swellings, referred to the radiology department, using either 3.5 or 5 MHz linear or sector probe. The histologic diagnosis was obtained for comparison where available.

Using histology as gold standard, the sensitivity and specificity of ultrasound appearance in diagnosing thyroid malignancy are 0% and 0% respectively. There was significant discordance between histological diagnosis and ultrasonographic appearances in benign thyroid disorders using established criteria.

The utility value of ultrasound in the diagnosis of benign and malignant thyroid diseases is however found to be limited, given its low sensitivity and specificity at the available power range (3.5 or 5.0MHz) in this centre.

Keywords: Thyroid, swelling, ultrasound, diagnosis, utility

Résumé

Correspondence to:

Dr. Mrs. A. A. Olatunji,
Department of Radiology,
Obafemi Awolowo College of Health
Sciences, Olabisi Onabanjo University,
P. M. B. 2002, Sagamu. Ogun State,
Nigeria.

Quoique le diagnostic du cancer peut seulement être confirmé par histologie, autres modalités diagnostiques telles que l'échographie, ce qui est bon marché et facilement disponibles, peuvent être utilisées comme des alternatives particulier où l'histologie n'est pas facilement disponible.

Cette étude a été faite à évaluer l'utilité ou autrement, de quelques apparitions échographique de prédire certaines pathologies thyroïdiennes, y compris le cancer.

Échographie des masses de la thyroïde a été réalisée avec un positionnement approprié chez les patients avec des gonflements du cou, appelés le service de radiologie, en utilisant soit 3,5 ou 5 MHz linéaire ou sonde du secteur. Le diagnostic histologique a été obtenu pour la comparaison lorsqu'elles sont disponibles.

À l'aide d'histologie comme étalon-or, la sensibilité et la spécificité de l'apparence des ultrasons dans le diagnostic de cancer de la thyroïde sont 0 % et 0 % respectivement. Il y a divergence significative entre diagnostic histologique et échographique apparitions dans les troubles bénins thyroïde à l'aide de critères établis.

La valeur de l'utilité des ultrasons dans le diagnostic des maladies thyroïdiennes bénignes et malignes se trouve toutefois être limité, étant donné sa faible sensibilité et la spécificité à la puissance disponible varie (3,5 ou 5.0 MHz) dans ce centre.

Introduction

A normal thyroid gland is located in the anterior part of the neck, the lateral lobes lying on either side of the trachea, connected across the midline by the isthmus. In obese patients it may lie a bit more caudal in position. In some normal individuals (10-40%), a third thyroid lobe may be found (the pyramidal lobe) extending upward from the

thyroid close to the midline in the suprahyoid region, in front of the thyroid cartilage. In longitudinal planes the thyroid lobes usually have oval shape with a slender elongated upper pole and a rounded inferior pole. The normal thyroid parenchyma has homogeneous echoes of greater intensity than the adjacent strap muscles, limited by a thin highly reflective capsule¹

Malignant neoplasm of the thyroid is uncommon with a uniform world incidence of 40 per million and accounts for less than 1% of all malignancies. It is seen from childhood to old age with a peak in sixth decade of life in Europe and America as against fourth in Africa and Asia. It is three times more common in females². The mode of diagnosis of thyroid swellings in Nigeria includes the use of radiologic and non-radiologic methods. While the non radiologic investigative methods include measuring the amount of circulating thyroxine (T4) levels, the tri-iodothyronine T3 in blood, serum TSH, and Thyroid Releasing Hormones, the radiologic methods include plain film evaluation, radioisotope uptake tests which is used in the assessment of the functional activity of thyroid nodules and diagnosis of hyperthyroidism. Fine needle aspiration cytology and direct laryngoscopy are other age old ways of investigating thyroid swellings.

Ultrasonography (US) and lately Computerized Axial Tomography (CT and Magnetic Resonance Imaging (MRI) are relatively recent in use as imaging modalities of thyroid diseases. Thyroid ultrasound is capable of differentiating solid from cystic lesion, solitary nodules from multinodular and diffuse enlargement and extra thyroidal lesions³. In general there is no ultrasound pattern which may be considered typical for a specific variety of thyroid cancer. While coarse intranodular calcifications can be found in both benign and malignant lesions, micro calcifications are said to be a reliable sign of malignancy¹. The halo seen in malignancy are said to be irregular in thickness and incomplete. Two-thirds of malignant neoplasms are predominantly echo-poor relative to the normal thyroid parenchyma.

Less frequently encountered are isoreflexive (<25%) and mixed (<10%) halo types. The margin of a malignant mass is poor with an irregular echo pattern.

No specific Doppler features are known to be associated with malignant thyroid diseases. The reliable indicators of malignancy are evidence of infiltration of structures around the thyroid and metastasis to cervical lymph nodes¹. This present study was carried out to examine the reliability of ultrasound (at the currently most available power range in the hospitals) in the diagnosis of thyroid mass using histological diagnosis as the gold standard, with a view to assessing its utility and saving both cost and time to facilitate early intervention.

Materials And Methods:

A total of 311 patients who attended the surgical and general outpatient's department of the tertiary health care facility located in the North central geopolitical zone of Nigeria for complaints about neck swellings within a period of 5 years were entered in the study. Consent was obtained from each patient verbally as investigation was part of normal routine done for all such patients in the hospital. Ethical consent was also obtained in principle at the onset of study from the Ethics and Research Committee of the Hospital through its chairman. The demographic data was obtained from the patients request card.

A Siemens's type of ultrasound machine using either a 3.5 or 5.0 MHz. sector transducer with the use of a stand-off pad, was used in assessing the patients. The patients were scanned lying supine on the couch with a support at the shoulders and neck extended to expose the thyroid gland more prominently in the anterior neck region. A longitudinal and transverse scan was thus performed on the thyroid gland while making adequate assessment of it. The echo-texture, outline, and presence of nodules, halo, or any calcific structures were noted and recorded. A mass was considered to be malignant on ultrasound if it has a combination of some of the following: surrounding halo, irregular outline, distorted echo pattern, echogenic or hypoechoic focal nodules, and, or calcification¹. See

Figures 1 and 2.

The presence or absence of neck lymph node enlargement and any retrosternal extension of the thyroid gland was also recorded.

The surgeon involved in the study then either booked the patient for excisional biopsy, and, or subtotal thyroidectomy with the specimen sent to histopathology laboratory for histological diagnosis depending on the management options available and which was of best clinical advantage to the patient. The histology results were retrieved where available and used as the gold standard to assess ultrasound diagnoses.

The sensitivity and specificity of ultrasound diagnosis were computed using the 2 X 2 table. Sensitivity = True Positive/True Positive + False Negative

Specificity = True Negative/True Negative + False Positive

Results

The total number of female patients in the study was 234 while the males were 68. The mean age of the study subjects was 38.0 ± 14.7

years with a range of 2-75 years.

Of the 311 patients scanned, a total of 102 patients had histology report done on their post surgical specimens. Ninety-five (95) patients were diagnosed by histology as having colloid goitre, five as malignant, and 2 as non-malignant and non-goitre. Of these, only 62 were recognised by ultrasound as colloid goitre, 10 as malignant, while 28 as non-malignant non-goitre, while 2 are normal. Ten samples diagnosed as colloid goitre by histology were diagnosed as malignant by ultrasound using features of irregularity of outline, calcification, and presence of nodules. Histology and Ultrasound agreed on negative diagnosis of Colloid goitre in only 2 cases.

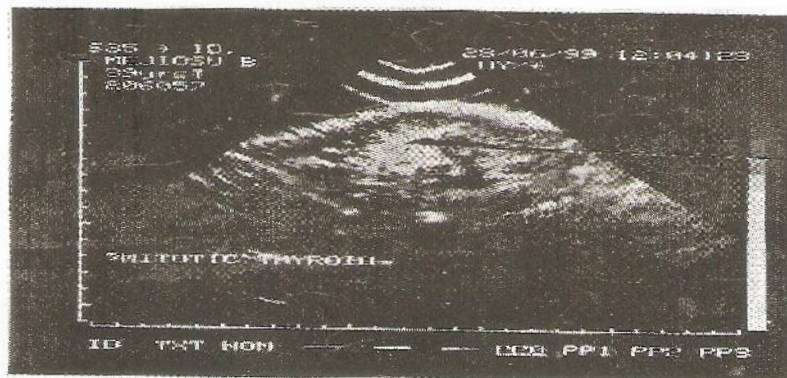
All five patients diagnosed by histology as malignant were recognised by ultrasound as non-malignant. See Tables 1 and 2. The sensitivity and specificity of diagnosis of Colloid Goitre by ultrasound modality were 60% and 28.5% respectively, while that for malignancy is 0 and 0, respectively.

The other patients could not be assessed since there were no histology results to serve as gold standard.

Discussion

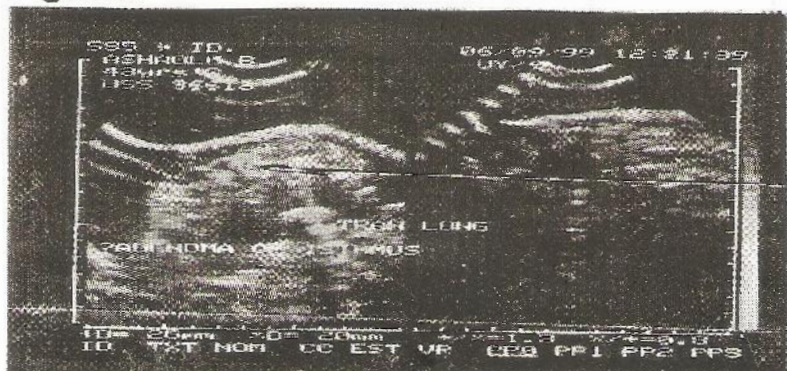
The female:male ratio in this study was 234:68

Figure1



Echogenic nodule with surrounding halo

Figure2



Distortion & Calcification

(3:1), which is in agreement with the findings of other workers in literature that found that

Table 1: Sensitivity and Specificity of Ultrasound diagnosis of Colloid Goitre against Histology

		Histology	
		positive	negative
Ultrasound	positive	57	5
	negative	38	2
Total		95	7

Table 2: Sensitivity and Specificity of Ultrasound diagnosis of Malignant Thyroid disorders against Histology

		Histology	
		positive	negative
Ultrasound	positive	0	10
	negative	5	0
Total		5	10

thyroid cancer occurred more commonly in women^{2,4}. The age range of 2-75 is consistent with the fact that thyroid cancer is common in all age groups. However, the number of patients in this study was too few to examine the young population for the frequency of papillary thyroid cancer which has been shown to be more frequently in them than follicular cancer with a peak age of 30-50 years⁵. High resolution ultrasound is the best imaging modality for objectively detecting size, number and cellular nature of the nodules⁶. A detailed study of the thyroid gland is expected to be done with a 7.5-10MHz. However, 5MHz linear or convex array probes which are a medium frequency probe can also be used with stand off pad to reduce near field artefacts and provide optimal contact with the skin. In this study, most of the patients were done with 5MHz probe, although some of the patients had to be done with 3.5MHz sector probe when there was system breakdown as often happens because of overuse and poor maintenance. This may actually account for the specificity and sensitivity results in the Study. It is now established that although ultrasonography is very important and is very necessary in the imaging of swellings in the

neck, it has a serious set back in differentiating between benign and malignant nodules⁷. By way of typical ultrasound description, neither the test for regularity of outline, calcification nor the descriptive word as colloids were diagnostic of the swellings seen in this study as malignant. This finding is in agreement with other researchers in literature who worked in other parts of the world and with varying numbers of patients^{1,3,7,8,9}. Moon et al¹⁰ in their own study concluded that ultrasonography has an acceptable malignancy-predicting value in selected patients with thyroid nodules. They, however commenting on the high rate of indeterminate results from it say this precludes the imaging modality from being a standard independent diagnostic method for the present time¹⁰. In discussing retropharyngeal node metastasis from papillary thyroid carcinoma, Otsuki N. et al¹¹ concluded that routine ultrasonography of the neck will miss the metastasis in the retropharyngeal nodes. Hence a periodic CT scan or MRI is recommended for follow up of those patients especially with a history of neck dissection. A call for a combination of conventional US and Colour Flow Doppler sonography (CFDS) was made to increase the screening sensitivity and accuracy in distinguishing malignant thyroid nodules¹². Pulsed and power Doppler echography may provide important information about the vascular pattern and the velocimetric parameters. Such information can be further useful preoperatively to reach a correct differential diagnosis of malignant or benign thyroid lesions⁵. Nuclear imaging is also said to be a useful modality for the functional characterization of a thyroid nodule. A hypoactive solid nodule in nuclear scanning, points out increased risk of malignancy⁶. However, after imaging modalities, FNAC, is the preferred method for preoperative pathologic evaluation.

Conclusion

An adequate assessment of the pre surgical condition of patients with neck swellings should include conventional ultrasound to diagnose simple cysts, multinodular and multicystic goitres. However, when the consideration is higher for thyroid carcinomas,

an ultrasound request should be considered as an adjuvant to a guided biopsy. This will enable the surgeon to take an informed conservative approach where appropriate.

References:

1. Luigi Solbiati, Fausto Crose. Thyroid and Parathyroid gland. In: David Cosgrove, Hylton Meire, Keith Dewbury .Editors. *Abdominal and General Ultrasound, Vol 2.* London: Churhill Livingstone, 1994:661-671.
2. Badoe EA, Archampong EQ, Jaja MOA . Principles and practice of surgery including pathology in the tropics.2nd Accra, Ghana publishing corporation.1994; 304-323.
3. Walker J, Findlay D, Amar SS, Small PG, Wastie ML, Pegg CAS. A Prospective study of thyroid ultrasound scan in the clinically solitary thyroid nodule. *The British Journal of Radiology*, July1985; 58:617-619.
4. Onyia JN, Forrest LA, Forsthoefel K. Pappillary Carcinoma associated with Black Thyroid Gland. *American Journal of Otolaryngology*, 1996; 17(5): 299-302.
5. Santacrose L, Garigliardi S, Kennedy AS, Balducci L, Talavera F, McKenna R, Harris JE. Thyroid, Pappillary Carcinoma. *East Afr Med J.* 2004; 81(9): 459-62. Medline 2010 Sept.
6. Gurleyik E, Coskun O, Aslander A. Clinical Importance of Solitary Solid Nodule of The Thyroid in Endemic Goitre Region. *Indian J of Med Sciences.* 2005; 59(9): 388-395.
7. Oglivie JB, Piatigorsky EJ, Clark OH. Current status of fine needle aspiration for thyroid nodules. *Adv Surg.* 2006; 40: 223-38.
8. Wang N, Xu Y, Ge C, Guo R, Guo K. Association of sonographically detected calcification with thyroid carcinoma. *Head Neck.*2006; 28:1077-83.
9. Sahin M, Gursoy A, Tutuncu NB, Guvener DN. Prevalence and prediction of malignancy in cytologically indeterminate thyroid nodules. *Clin Endocrinol (Oxf).* 2006; 65: 514-8.
10. Moon HG, Jung EJ, Park ST, Ha WS, Choi SK, Hong SC, Lee YJ, Joo YT, Jeong CY, Choi DS, Ryoo JW .Role of ultrasonography in predicting malignancy in patients with thyroid nodules. *World J Surg* 2007; 31:1410-6.
11. Otsuki N, Nishikawa T, Iwae S, Saito M, Mohri M, Nibu K. Retropharyngeal node metastasis from papillary thyroid carcinoma. *Head Neck.* 2007; 29: 508-11.
12. Appetecchia M, Solivetti FM, The association of colour flow Doppler sonography and conventional ultrasonography improves the diagnosis of thyroid carcinoma. *Horm Res .*2006; 66: 249-56. Epub 2006 Oct 2.