

Thyroid calcification: radiographic patterns and histological significance

*Ganiyu A Rahman¹, Adekunle Y Abdulkadir², Kolawole T Braimoh²

¹ Department of Surgery, University of Ilorin Teaching Hospital, Ilorin, Nigeria

² Department of Radiology, University of Ilorin Teaching Hospital, Ilorin, Nigeria

* Currently at the College of Medicine, King Khalid University / Asir Central Hospital, Abha, Kingdom of Saudi Arabia

Corresponding author:

Ganiyu A Rahman
Department of Surgery
University of Ilorin Teaching Hospital,
Ilorin, Nigeria.
garahman1@yahoo.com

Background. Calcification of the thyroid gland may occur in both benign and malignant thyroid diseases. **Aim.** To determine the incidence, significance and plain radiographic patterns in goiters with calcification. **Materials and Methods.** Radiographs (chest, thoracic inlet and neck) and clinical records of 160 goiterous patients were reviewed retrospectively, and classified into two groups; those with calcification and those without calcification. Data analysis was by SPSS 11.0. **Results.** The majority of our patients (64.9 %) were in their 4th to 6th decade of life with modal age of 30 years. The ratio of males to females was 3: 17. Radiographic calcification was demonstrable in 17.0% (male 22.2% and female 77.8%) and this increased steadily by about three-fold per decade of life from 3rd-5th decade. All patients with calcification had tracheal narrowing, higher occurrence of cervical degeneration and 3-fold incidence of retrosternal extension of goitres. However, only four out of thirteen patients (14.8%) with malignant histology had calcification, while the remaining nine patients had no calcification. Subtotal thyroidectomy was offered in 89.3% of patients with calcification. **Conclusion.** Calcification of goitre increases steadily with advancing age and is more common in multinodular than solitary thyroid nodules. However, it does not suggest benignity or malignancy of the thyroid mass. There is high propensity of calcification in goitres having retrosternal extension and a strong tendency for concentric tracheal narrowing in calcified goitres. Hence, this may make the need for early thyroidectomy imperative.

Keywords: Cervicothoracic radiograph, Goiters, Thyroid calcification, Thyroidectomy, Thyroid histology.

Received: 2 September 2008
Accepted: 18 November 2008

Introduction

Calcification within the thyroid gland may occur in both benign and malignant thyroid diseases. In 1958 Holtz and Powers (1)

presented their work on thyroid calcification in papillary carcinoma of the thyroid gland. Thereafter, several authors have written on the significance of thyroid calcification, a common finding on thyroid imaging (1-4).

More recently, sonographically detected thyroid calcifications were related to the risk of cancer (5–10), but there is no agreement yet on the distinct ultrasonographic features that could distinguish benign from malignant thyroid nodules (9). Calcifications, often described in sonographic or radiographic reports, can be detected in both benign and malignant thyroid nodules. Peripheral calcification in thyroid nodules according to Kim et al (8), often presents a sonographic diagnostic dilemma to radiologists because its acoustic shadowing may hinder the visualization of the nodule internal architecture. In addition, the characteristics of thyroid nodules on ultrasound (US) can vary widely between observers. These two ultrasonography limitations are unlikely with the plain radiographs explored in this study.

Neck, thoracic inlet and chest radiographs are part of the preoperative work-up in patients with goitre at our centre. Apart from soft tissue swelling, evaluation of the trachea, oesophagus and cervical vertebrae, calcification in the thyroid swelling can be significant. This is an observational study aimed at determining the incidence of calcification in the various types of goiters and evaluating the importance of the various types of calcification.

Materials and Methods

All patients who had neck, thoracic inlet and chest radiographs for goiters were retrospectively reviewed. The patients' records were reviewed for clinical findings, preoperative radiological investigations, type of surgical operation and histological diagnosis. Only patients who had surgical operations and histological diagnosis were included in the study. The radiographs of this group of patients were reviewed for the extent of the goiter, calcifications, retrosternal extension, cervical vertebral configuration and bony changes. We grouped our patients into two

groups; 1) patients with calcification in goiter (CIG) and 2) no calcification in goiter (NCIG) for the purpose of analysis. The data was analysed using SPSS 11.0.

Results

The 160 goiterous patients composing of 136 (85.0%) females and 24 (15.0%) males, who had neck, thoracic inlet and chest radiographs were evaluated. The majority (25.2%) of patients were in the 5th decade of life, followed by patients presenting in the 3rd decade (20.8%) [Fig 1]. The modal age at hospital presentation was 30 years. Calcification in goiter (CIG) was radiographically demonstrable in 27 (17.0%) patients whose ages ranged from 23 years to 70 years with modal occurrence at 45–years. There was a steadily increasing CIG of about three folds with each decade of life from the 3rd–5th decade and there was no occurrence before 23 years of life. Patients below 23 years accounted for 6.3% of our total patients and all belong to the NCIG group (Table 1). Amongst the twenty-seven (17.0%) patients who had their enlarged thyroid gland calcified there were six male (22.2%) and 21 female (77.8%). Amorphous and mixed types of calcification constituted about 63% with flat and curvilinear variants very rare [Table 1]. Sampled radiographs illustrating calcifications are shown in figures 2–4.

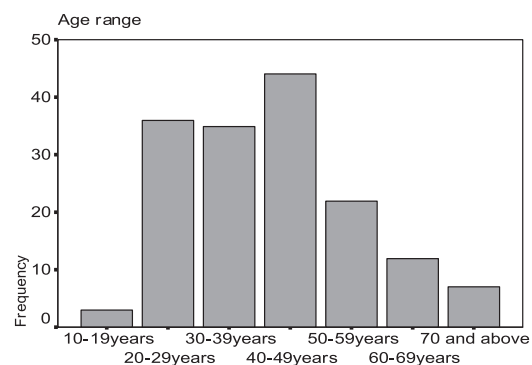


Figure 1 Age distribution of patients with goitres

Table 1 Cross Tabulation of Patient Age Groups with Calcifications and Types

Patients' Age Group	CIG group		NCIG group		Calcification types in CIG group					
	Frequency [n]	Percentage [%]	Frequency [n]	Percentage [%]	Nodular	Flat	Curvilinear	amorphous	Mixed	cloudy
20–29 years	1	3.7	3	2.3	–	–	–	–	1	–
30–39 years	3	11.1	32	24.1	–	–	–	2	1	–
40–49 years	8	29.6	28	21.1	–	–	–	2	2	4
50–59 years	6	22.2	32	24.1	2	–	–	2	1	1
60 years Above	8	29.6	15	11.3	–	–	1	2	4	1
Unsure	1	3.7	12	9.0	–	1	–	–	–	–
Total	27	100.0	133	100	2	1	1	8	9	6

Pre-operative diagnosis in these patients showed that 104 (65.4%) had simple multinodular goitre, 36 (22.6%) had toxic goitre, five (3.1%) had solitary thyroid nodule and 11 (6.9%) had malignant goitre. Histological diagnosis showed colloid 147 (91.9%) as the most common with thirteen (8.2%) having malignant goitre. Follicular carcinoma was

the commonest type of thyroid malignancy (Table 2).

Various forms of tracheal narrowing were present in association with CIG. In 74.1% of CIG, there is circular tracheal narrowing in contrast to the 58.6% occurrence in the NCIG. Importantly, there was no patient with CIG without tracheal narrowing

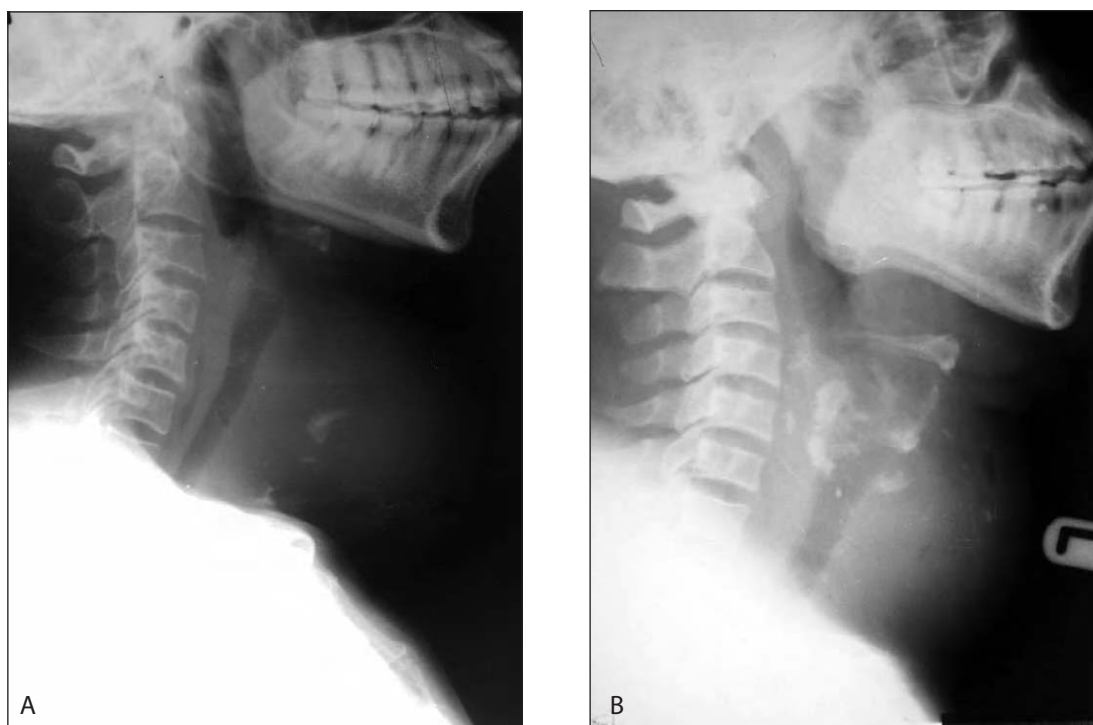


Figure 2 Lateral neck radiographs showing mixed calcifications (nodular and flat). Note tracheal narrowing and air oesophagogram in [A]

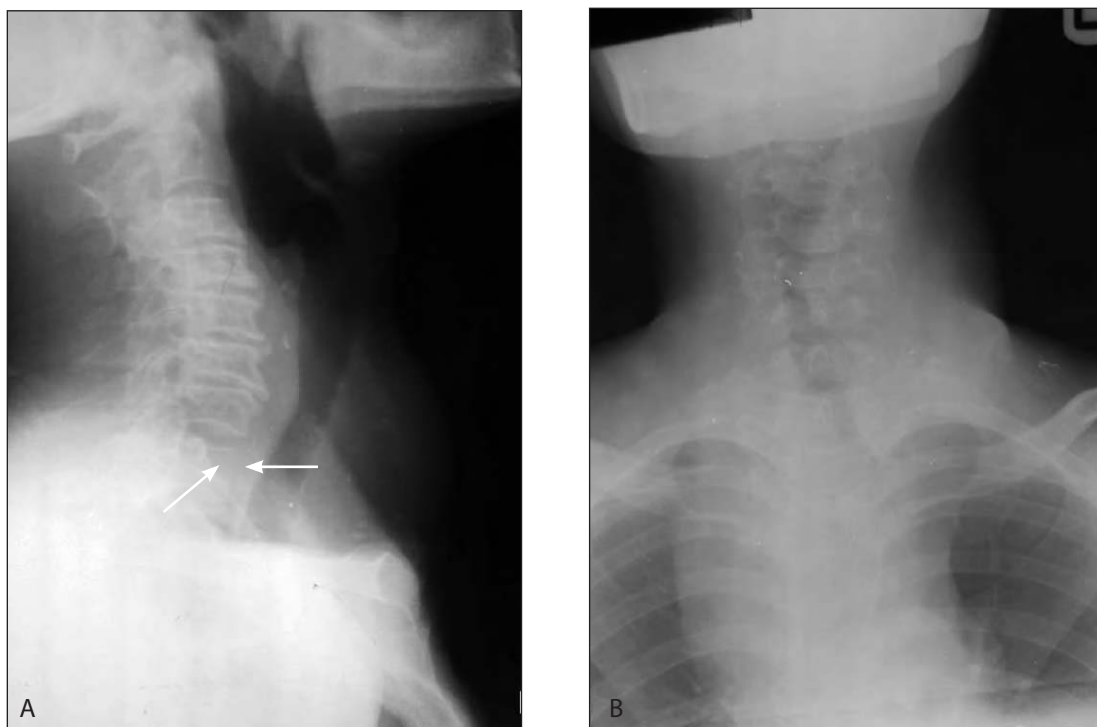

Figure 3 Lateral neck and frontal thoracocervical radiographs of a patient with malignant goitre having retrosternal extension. [A] Showing wide spread nodular calcifications in goitre, cervical osteophytes and erosion of the anterior body of T1 and [B] retrosternal extension with tracheal deviation

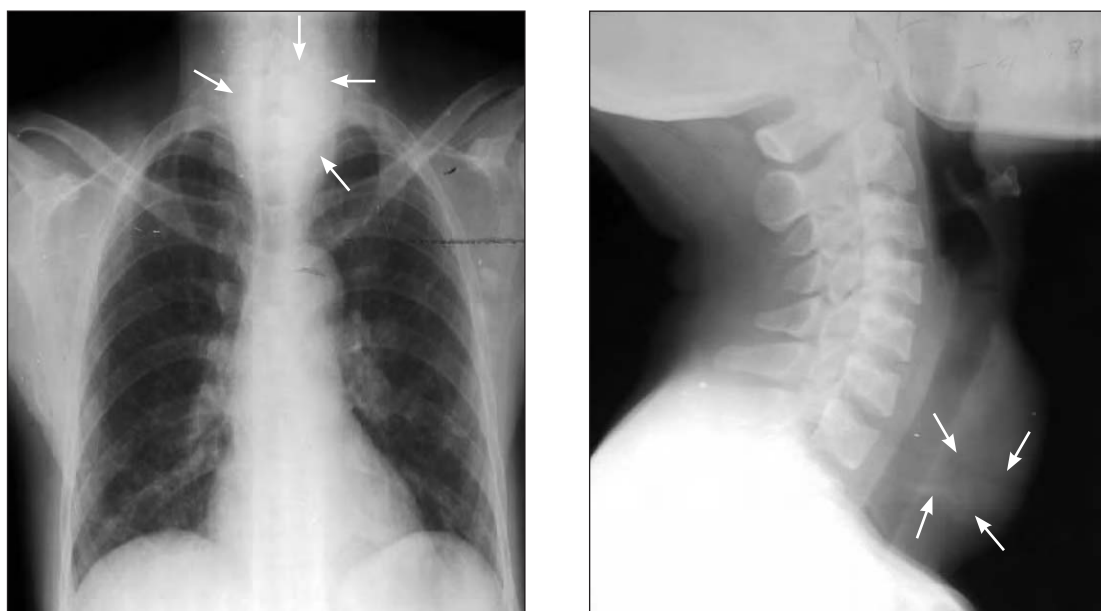


Figure 4 Frontal chest and cervical radiographs of a patient demonstrating cloudy calcification. Note the lobulated mass in the left hilum

Table 2 Histological Variance Cross Tabulation to Calcifications and Types

Histological types	CIG group		NCIG group		Types of calcifications					
	Frequency [n]	Percentage [%]	Frequency [n]	Percentage [%]	Nodular	Flat	Curvilinear	Amorphous	Mixed	Cloudy
Colloid goitre	23	85.2	124	93.2	2	1	1	8	7	4
Follicular carcinoma	3	11.1	5	3.8	-	-	-	-	2	1
Papillary carcinoma	1	3.7	2	1.5	-	-	-	-	-	1
Poorly differentiated	-	-	2	1.5	-	-	-	-	-	-
Total	27	100	133	100	2	1	1	8	9	6

Table 3 Types of Tracheal Narrowing Cross Tabulation to Calcifications and Types

Tracheal Narrowing	CIG group		NCIG group		Types of calcifications						Total
	Frequency [n]	Percentage [%]	Frequency [n]	Percentage [%]	Nodular	Flat	Curvilinear	Amorphous	Mixed	Cloudy	
No narrowing			13	9.8	-	-	-	-	-	-	-
Anteroposterior narrowing	3	3	17	12.8	-	-	-	-	2	1	3
Transverse narrowing	4	4	25	18.8	-	-	-	2		2	4
Concentric narrowing	20	20	78	58.6	2	1	1	6	7	3	20
Total	27	27	133	100	2	1	1	8	9	6	27

Table 4 Relates neck and chest findings to the thyroid groups [CIG and NCIG]

Thyroid group	Tracheal deviation			Retrosternal extension		Cervical degeneration		Air oesophagogram		Heart	
	Central	Left	Right	Yes	No	Yes	No	Yes	No	Normal	Enlarged
CIG	11 [40.7%]	4 [14.8%]	12 [44.4%]	17 [63.0%]	10 [37.0%]	13 [48.1%]	14 [51.9%]	5 [18.5%]	22 [81.5%]	15 [55.6%]	12 [44.4%]
NCIG	57 [42.9%]	30 [22.6%]	46 [34.6%]	27 [20.3%]	106 [79.7%]	42 [31.6%]	91 [68.4%]	37 [27.8%]	96 [72.2%]	86 [64.7%]	47 [35.3%]

(Table 3). The sagittal and transverse internal tracheal diameters were reduced to less than 1.2cm in 51.9% and 74.1%; and 43.6% and 54.4% in CIG and NCIG patients respectively.

The cervical spine shows predominant straightening in CIG, unlike the normal lordosis that predominated in NCIG (Table 3). The patterns of cervical degenerative changes

were similar in both groups affecting c5 vertebra in 40.7% of CIG and 36.3% NCIG. However, the occurrence of cervical degeneration was much higher in CIG – 48.1% in comparison to the 31.6% in NCIG. There was retrosternal extension of goiters in 63.0% and 20.3% of patients with CIG and NCIG respectively. Other neck and chest findings are summarized in Table 4.

Of the patients with CIG, 23 (85.2%) had colloid goitre, three (11.1%) had follicular carcinoma and one (3.7%) had papillary carcinoma. Nine of the thirteen patients who had malignancy confirmed histologically had no calcification [Table 2].

The majority 25 (92.6%) of patients with CIG had subtotal thyroidectomy; only two (7.4%) had total thyroidectomy.

Discussion

Thyroid gland calcification is not uncommon and has been reported by various authors (1-4). There are three radiographic patterns of intrathyroid calcification: eggshell, dystrophic and fine stippled psammomatous calcification (6-11). Although this is not part of the aim of this study, several recent sonographic reports focused on thyroid calcifications have described similar patterns of calcification that include microcalcification, coarse and dense calcification, and rim-like peripheral calcification (7-10). However, the ultrasonic differentiation between malignant nodules and benign nodules based on calcification is still controversial. In a similar vein, studies correlating the histopathological and radiographic significance of thyroid calcifications are rare in the literature.

In this study, 17.0% patients with goitre had thyroid calcification. This is similar to Komolafe's finding in a similar environment (12). The radiological patterns of calcification were described as nodular, flat, curvilinear and cloudy (12). However, some patients present with a mixed pattern. Amorphous and mixed types of calcification constituted 66.7% of CIG in this study which is different from the findings of nodular variants in 72.6% in Komolafe's study (12). The probable explanation for this variation may be the patients' earlier presentation for medical intervention due to increasing awareness as evidenced by the modal age of 30 years at intervention in this study (Table 2).

We found out that CIG steadily increases by about three fold with each decade of life from the 3rd to the 5th decade (Table 1). Importantly, there was no occurrence of CIG amongst the 10 (6.3%) patients younger than 23 years. Again our findings of only four cases of CIG occurring before 42 years of age show that age is an important determining factor of calcification. This may not be unrelated to the length of time that may be required to have sufficient calcium deposition for a calcific focus to be sufficiently opaque on radiography.

The majority (65.4%) of the goiters in this study were simple multinodular goitres with only 6.9% presenting with a solitary nodule. Khoo et al (6) suggested that when calcification is noted within a solitary thyroid nodule, the risk of malignancy is very high. In this study, none of the patients with a solitary nodule had calcification. Of the patients with CIG, 85.2% had histological diagnosis of colloid goitre and 14.8% had malignant goitre. Calcification was found in 31% of patients with malignancy, with 69% of them not having any calcification. Amongst patients with CIG who had malignancy confirmed histologically, 75% of them had follicular carcinoma. Thus, follicular thyroid cancer is the commonest thyroid cancer to calcify with about 3-fold occurrence when compared to NCIG (see Table 2). Similar to other studies from Nigeria (13, 14), follicular carcinoma is the most common type of thyroid cancer in both CIG and NCIG. This study further confirms that calcification can occur in both benign and malignant goitres, though some studies have shown that calcifications were significantly more frequent in malignant goitres than simple multinodular goiters (15). The calcification in benign goitres can be explained from the point of view of haemorrhage, tissue necrosis and epithelial degeneration, which are factors that predispose to dystrophic calcification (12).

All patients with CIG had associated tracheal narrowing with predominance of concentric narrowing in 20 (74.1%). This is in contrast to the occurrence of 58.6% in the NCIG group. Again, in 63.0% of patients with CIG, there was retrosternal extension of goitres as against 20.3% in NCIG. Thus, we infer that CIG have about 3 times greater association with retrosternal goiters. Retrosternal extension may result in vascular compression leading to damping of blood or stasis and subsequent reduced perfusion, which in turn may promote ischaemia and necrosis, thereby playing a role in increasing the incidence of calcification. Cardiac enlargement, which is a recognized finding in thyrotoxic goitre, occurs with a higher frequency in CIG (44.4%) than NCIG (34.6%) as shown in Table 4.

The cervical spine curvature in CIG is essentially lordotic or straightened. The findings of no single case of CIG with kyphosis or scoliosis may show the protective mechanism to reduce the compressive effect of the calcified goiters, which becomes more rigid, on the trachea.

Calcification of goitre is more common in multinodular than solitary thyroid nodules and steadily increases with advancing age. However, the presence of calcification does not suggest benignity or malignancy of the thyroid mass. In malignant goitres, follicular variance is the most common to calcify with about a 3-fold chance of occurrence. There is high propensity of thyroid gland calcification in goitres having retrosternal extension. Similarly, CIG also has a strong tendency to produce concentric tracheal narrowing. Hence, this may create the need for early thyroidectomy imperative.

References

1. Segal RL, Zuckerman H, Friedman EW. Soft tissue roentgenography: its use in diagnosis of thyroid carcinoma. *J Am Med Assoc.* 1960;173:1890-94.
2. Erazo ST, Wahner HW. Roentgenographic diagnosis of thyroid cancer in the presence of endemic goiter. *AJR Am J Roentgenol.* 1966;96:596-603.
3. Margolin FR, Steinbach HL. Soft tissue roentgenography of thyroid nodules. *AJR Am J Roentgenol.* 1968;102:844-52.
4. Park C.H, Rothermel FJ, Judge DM. Unusual calcifications in mixed papillary and follicular carcinoma of the thyroid gland. *Radiology.* 1976;119:554.
5. Kakkos SK, Scopa CD, Chalmoukis AK, Karachalios DA, Spiliotis JD, Harkoftakis JG. Relative risk of cancer in sonographically detected thyroid nodules with calcifications. *Clin Ultrasound.* 2000;28:347-52.
6. Khoo ML, Asa SL, Witterick IJ, Freeman JL. Thyroid calcification and its association with thyroid carcinoma. *Head Neck.* 2002; 24: 651-5.
7. Taki S, Terahata S, Yamashita R, Kinuya K, Nobata K, Kakuda K. Thyroid calcifications: sonographic patterns and incidence of cancer. *Clin Imaging.* 2004; 28:368-71.
8. Kim EK, Park CS, Chung WY, Oh KK, Kim DI, Lee JT et al. New sonographic criteria for recommending fine-needle aspiration biopsy of non-palpable solid nodules of the thyroid. *AJR Am J Roentgenol.* 2002;178(3):687-91.
9. Kim MJ, Kim E, Kwak JY, Park CS, Chung WY, Nam K, et al. Differentiation of Thyroid Nodules With Macrocalcifications: Role of Suspicious Sonographic Findings. *J Ultrasound Med.* 2008; 27:1179-84.
10. Yoon DY, Lee JW, Chang SK, Choi CS, Yun EJ, Seo YL et al.. Peripheral calcification in thyroid nodules: ultrasonographic features and prediction of malignancy. *J Ultrasound Med.* 2007;26(10):1349-55.
11. Yuzbasioglu MF, Ozkaya M, Ezberci F, Senoglu N, Kizildag B. Eggshell calcification after intrathyroidal hemorrhage of retrosternal thyroid. *Cases J.* 2008 25;(1):11.
12. Komolafe F. Radiological patterns and significance of thyroid calcification. *Clin Radiol.* 1981;32:571-5.
13. Olurin EO, Timeyin ED, Adenuga MO. Thyroid gland diseases in Ibadan – A review. *West Afr J Med.* 1986;5:147-55.
14. Adeniji KA, Anjorin AS, Ogunsulire IA. Histological Pattern of Thyroid Diseases In A Nigerian Population. *Nig Quart J of Hosp Med.* 1998;8:241-4.
15. Consorti F, Benvenuti C, Boncompagni A, Giovannone G, Moles N, Scardella L. Clinical significance of thyroid nodule calcification. *G Chir.* 2003; 24 (3):78-81.