

# Plastination: a modern approach to chiropractic teaching

Gilles Grondin\*

---

*Plastination is a unique method for the preservation of biological material for teaching and research. The plastinated specimens are dry, odorless, non-toxic and durable. They can be manipulated by teachers and students without protective equipment like gloves.*

*Invented in 1978 by Doctor Gunther von Hagens from the University of Heidelberg, this technique, that involves the replacement of water by a curable polymer, has spread rapidly all around the world and is actually used in over 250 universities and colleges. To our knowledge, the Université du Québec à Trois-Rivières, is the first institution to use plastinated specimens for teaching anatomy, neuroanatomy, pathology and radiology to students in chiropractic.*

*This paper describes the various steps of the method (fixation, dehydration, impregnation and curing) and presents some examples of the utilization of plastinated specimens.*

(JCCA 1998; 42(2):107-112)

**KEY WORDS:** plastination, anatomy, pathology, teaching, research.

---



---

*La plastination constitue une méthode unique pour la préservation du matériel biologique pour fin d'enseignement ou de recherche. Le spécimen plastiné est sec, sans odeur, non toxique, durable et peut être manipulé tant par les enseignants que par les étudiants sans la nécessité du port de gants ou de tout autre vêtement protecteur.*

*Inventée en 1978 par le Docteur Gunther von Hagens de l'Université de Heidelberg, cette technique, qui implique la substitution de l'eau par un polymère, s'est rapidement répandue à travers le monde et est actuellement utilisé dans plus de 250 universités ou collèges. L'Université du Québec à Trois-Rivières est la première institution à offrir l'utilisation de spécimens plastinés à des étudiants en Chiropratique pour leur apprentissage de l'anatomie, la neuroanatomie, la pathologie ainsi que de la radiologie.*

*Le présent article décrit les différentes étapes (fixation, déshydratation, imprégnation et durcissement) de la préparation de spécimens plastinés et présente des exemples de leur utilisation.*

(JCCA 1998; 42(2):107-112)

**MOTS CLÉS :** plastination, anatomy, pathology, teaching, research.

---



---

\* Département de Chimie-Biologie, Université du Québec à Trois-Rivières, Trois-Rivières, Québec, Canada.  
Address correspondence to: Gilles Grondin, Laboratoire d'anatomie humaine, Département de Chimie-Biologie,  
Université du Québec à Trois-Rivières, C.P. 500, Trois-Rivières, Qc, Canada G9A 5H7.  
Tel: (819) 376-5186. Fax: (819) 376-5084. email: gilles\_grondin@uqtr.quebec.ca

© JCCA 1998.

## Introduction

Plastination was invented in 1978 at the University of Heidelberg by Doctor Gunther von Hagens. The first paper describing this revolutionary method was published by Dr. von Hagens himself in 1979.<sup>1</sup> The technique rapidly expanded through human and veterinary teaching laboratories, first in Europe and North America, and now it is used in more than 250 universities and colleges around the world. A first "International Conference on Plastination" was held in April 1982 in San Antonio, Texas. In April 1986, participants to the 3rd International Conference on Plastination created the "International Society for Plastination". In January 1987,<sup>2</sup> the inaugural issue of the "Journal of the International Society for Plastination" was published. In July 1996, participants from 20 countries gathered in the University of Queensland, Australia to attend the 8<sup>th</sup> International Conference on Plastination.

The plastination technique permits the preparation of "real" specimens that are dry, odorless, durable, and non-toxic,<sup>3</sup> which can be used in the classroom as well as in laboratory. These characteristics permit teachers and students the opportunity to manipulate the specimens without the use of protective equipment like gloves. Since 1994, plastinated specimens have been used to teach anatomy and neuroanatomy to students in chiropractic at the Université du Québec à Trois-Rivières. They are highly appreciated by the students.<sup>4,5,6</sup>

## The polymers

The principle of plastination involves the substitution of a specimen's water and part of the lipids by a curable polymer. Three different groups of polymers are used. Each will produce specimens with appropriate physical characteristics. The most widely used polymer is made of silicone. It exists with different degrees of viscosity for various applications and produces three dimensional resilient and semi-flexible specimens (see Figures 1, 2, 3), mainly used for teaching purposes. The second group is composed of epoxy resin. This polymer produces thin transparent slices of body parts (see Figure 4) that are mainly used in teaching sectional anatomy and training in computed tomography, magnetic resonance imaging and ultrasound. The third group of polymer, made with polyester resin is exclusively used for the preparation of opaque brain slices. It's special characteristic enhances the color

difference between gray and white matter (see Figure 5).

## The process

The process may be summarized as follows: first, the biological specimen needs to be fixed. After, it's water and part of it's fat have to be substituted by an intermediary solvent (dehydration). In the third step (impregnation), the solvent will be replaced by the proper polymer that will then be cured to render it dry and easily usable.

## Fixation

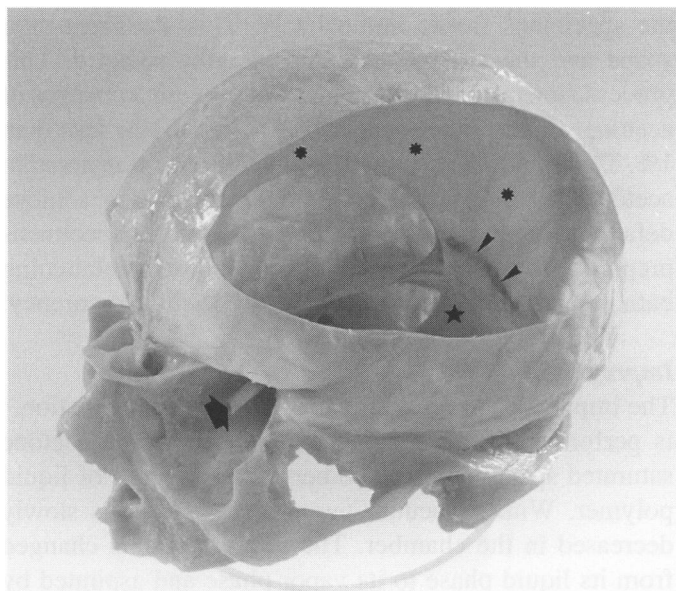
Any established fixation method using formalin solution in concentration between 5 and 20% can be used. To enhance color preservation, it is recommended to use a cold (4°C) Kaiserling solution<sup>7</sup> containing 5% of formalin to do the fixation. Specimens are generally fixed by injection through blood vessels (if these were not previously filled with coloring material), by infiltration (injection of the solution in the muscles with the help of a syringe and needle) or by immersion in the fixative solution. Depending on the size of the specimen and the fixation method used, this step will take between 1 and 3 weeks. Because of their high content in lipids, brains are recommended to be fixed in a high concentration of formalin solution over a longer period of time. Old museum specimens that have been kept in formalin for up to 10 years<sup>8</sup> can also be plastinated. The only restriction would be with specimens stored in a solution containing glycerol. These specimens would have to be rinsed off thoroughly to remove all the glycerol before being plastinated.

Coloring material can be injected into the blood vessels to illustrate the vascular system (see Figure 6), although this can only be done with fresh specimens, before fixation.

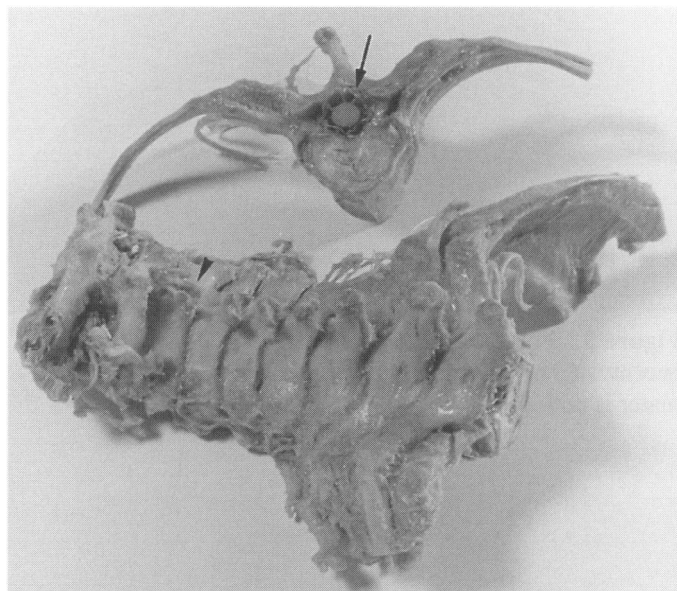
## Dehydration

The different polymers used for plastination are not miscible with water. Therefore, the specimens must be absolutely dehydrated. Their water must have been replaced by an intermediary solvent to permit the penetration of the polymer within the specimens. Dehydration can be achieved in stepwise ethanol baths, but the standard procedure is freeze substitution with acetone at -25°C.

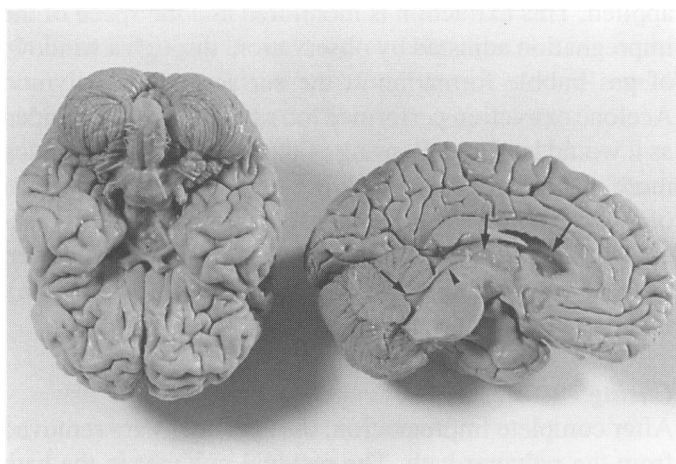
Specimens stored in glycerol should be dehydrated with



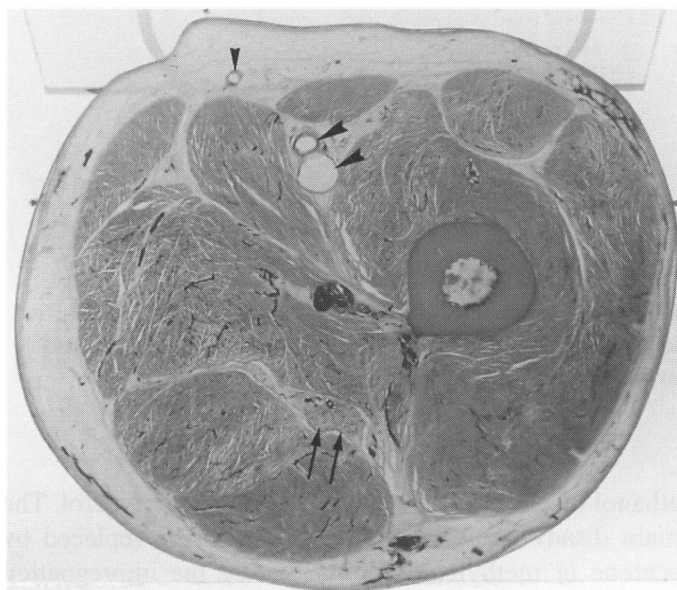**Figure 1 Silicone (S10) plastinated cerebral dura mater with the skull base.** The straight sinus (arrowheads) still filled with blood, optic nerve (arrow), falx cerebri (asterix) and tentorium cerebelli (star) are easily visualized.



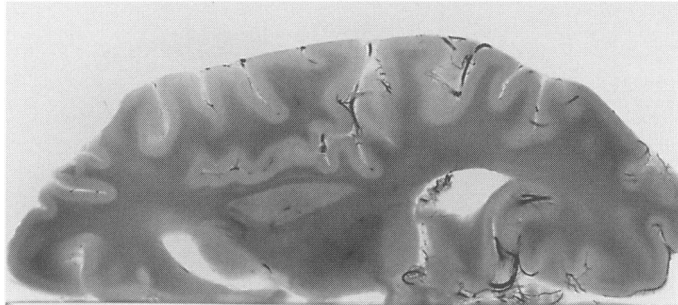
**Figure 2 Silicone (S10) plastinated spine sections.** Observe the spinal cord with its dura mater (arrow) and an anomaly at the level of the spinous process of C3 (arrowhead) which is oriented upward.



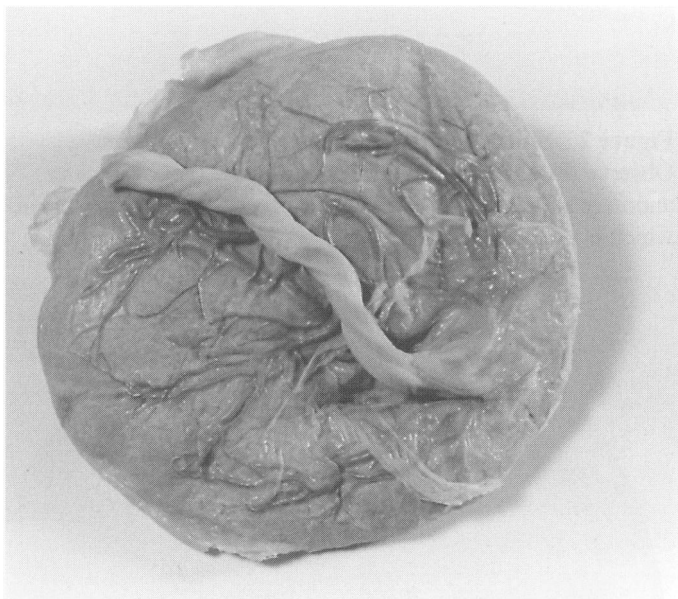
**Figure 3 Silicone (S10) plastinated brain and half brain.** The superficial origins of the cranial nerves are demonstrated as well as the lateral, third and fourth ventricles (arrows) and the cerebral aqueduct (arrowhead).



**Figure 4 Epoxy (E12) plastinated slice of the thigh.** Observe the great saphenous vein (small arrowhead), the femoral artery and vein (large arrowheads) and the sciatic nerve (arrows).



**Figure 5 Polyester (P35) plastinated half brain slice.** The accentuated color differentiation between grey and white mater is noticeable.



**Figure 6 Human placenta plastinated with silicone after injection of coloring material via the umbilical vein and arteries.**

ethanol to facilitate the complete removal of glycerol. The main disadvantage is that ethanol must be replaced by acetone or methylene chloride before the impregnation step. It will also cause considerable shrinkage of the specimens because it is generally performed at room temperature. Shrinkage must be avoided in order to obtain the most natural looking specimens.

Freeze substitution, performed directly in acetone, saves time. When immersed into cold acetone ( $-25^{\circ}\text{C}$ ),

the specimens freeze immediately. This stabilizes their shape and the shrinkage is considerably reduced. This process generally requires 3 to 5 weeks, with 3 changes of acetone. Finally, the content of water must be less than 1%. The lipid rich specimens now have to be transferred in acetone at room temperature for one week to achieve defatting and then they can be impregnated. Specimens prepared for epoxy plastination need an extra defatting bath in methylene chloride to improve their transparency.

### **Impregnation**

The impregnation process, called “forced impregnation,” is performed in a vacuum chamber where the acetone saturated specimens are submerged into a bath of liquid polymer. With a vacuum pump, the pressure is slowly decreased in the chamber. The acetone is then changed from its liquid phase to its vapor phase and aspirated by the vacuum pump. The extraction of the acetone creates a vacuum inside the specimens that forces the penetration of the polymer into them, down to their microscopic level.<sup>9</sup> Because of the great difference between the high vapor pressure of the acetone and the low vapor pressure of the polymer, only the acetone is extracted when the vacuum is applied. This extraction is monitored and the speed of the impregnation adjusted by observation, through a window, of gas bubble formation at the surface of the polymer. Acetone extraction performed too rapidly must be avoided as it would lead to collapsing of the specimen by the much more viscous polymer applying pressure outside instead of impregnating the specimens. Impregnation with silicone usually lasts 3 to 4 weeks, while epoxy or polyester, because of the thinness of the slices (2.5–4 mm), impregnate within a few days.

### **Curing**

After complete impregnation, the specimens are removed from the polymer bath. The residual polymer in the bath is still liquid and can be re-used for a subsequent impregnation. There are three specific curing techniques, depending on the polymer that is used.

The silicone impregnated specimens are exposed in a closed chamber to an atmosphere which is saturated with a gaseous hardener.<sup>10</sup> This step being performed at room temperature, the silicone expands and oozes from the specimens while warming up. These drippings must be wiped a few times during the first days of curing.

Generally, after 2 to 4 days, the surface is sealed and the specimens are available for demonstration or teaching activities. It is nevertheless recommended to store them in a sealed bag to accelerate complete curing which may take several months.

Curing of the epoxy resin impregnated specimens is performed by a heat treatment at 45°C. Final curing in an oven takes about one week.<sup>11</sup> Curing of brain slices impregnated with polyester is initiated by a 45 minute UV-light exposure and completed in an oven at 45°C for 5 days<sup>12</sup>.

### Conclusion

Even if the plastination technique may seem time consuming, it is a unique method that is worthwhile because the specimens prepared according to this technique are permanent and can be achieved at a relatively low cost.<sup>13</sup> They have proven extremely useful in teaching general gross anatomy,<sup>14,15,16</sup> sectional anatomy,<sup>17,18</sup> neuroanatomy,<sup>19,20,21,22</sup> pathology,<sup>23,24,25,26,27</sup> surgery,<sup>28,29,30</sup> as well as in research in embryology,<sup>31,32,33,34</sup> morphological sciences<sup>35,36,37,38,39</sup> and pathology.<sup>40,41,42,43,44</sup> Furthermore, compared to usual museum specimens in preservative jars, plastinated specimens are very attractive. This is why an exhibition of plastinated specimens held recently (July 15 to October 31, 1996) at Osaka, Japan drew a crowd of 250,000 people.<sup>45</sup>

We have employed plastinated specimens since 1994 at the UQTR to teach anatomy and neuroanatomy. We are still discovering the potential of these specimens for the teaching of pathology and radiology as well as to enhance continuing education. The results of two projects actually under evaluation in the field of radiological teaching will be presented at the 9th International Conference on Plastination, held July 5–10, 1998 at the Université du Québec à Trois-Rivières.

This material is also unique as a patient education tool. We will certainly see, in the near future, a doctor explaining to a patient the anomaly or pathology he is suffering from, with the help of a plastinated portion of spine presenting the same anomaly or pathology.

### Acknowledgments

The author wishes to thank Dr Peter Kogon for his advice during the preparation of this manuscript and Mr Claude Demers for his photographic expertise.

### References

- 1 von Hagens G. Impregnation of soft biological specimens with thermosetting resins and elastomers. *Anat Rec* 1979; 194(2):247–255.
- 2 Bickley H. A brief chronology of plastination. *J Int Soc Plastination* 1997; 12(2):37–38.
- 3 von Hagens G, Tiedemann K, Kriz W. The current potential of plastination. *Anat Embryol* 1987; 175(4):411–421.
- 4 Côté ME, Veilleux F, Christin MJ, Fortin MJ, Olry R. Plastination: a new approach to the teaching of topographical anatomy. Chiropractic Centennial Foundation, Washington, DC, USA, 1995.
- 5 Olry R, Grondin G. Plastination in chiropractic teaching: critical analysis and place of plastinated specimens in anatomical pedagogics. 7th Int Conf Plast, Graz, Austria, 1994. Abstract in *J Int Soc Plastination* 1995; 9(1):21.
- 6 Boulianne S, Giguère C, Grondin G, Olry R. Plastination cérébrale (S10, P40) et enseignement de la neuro-anatomie. 64è Congr Acfas, Montréal, Québec, Canada, 1996. Abstract in Programme général du 64è Congrès de l'ACFAS 1996: 111.
- 7 Kessler R: Farberhaltende Fixations – und Konservierungstechnik für Feucht-präparate. *Der Präparator* 1989; 35(4):161–170.
- 8 Cannas M, Fuda P. Plastination of old formalin-fixed specimens. *J Int Soc Plastination* 1991; 5(1):11–15.
- 9 Grondin G, Grondin GG, Talbot BG. A study of criteria permitting the use of plastinated specimens for light and electron microscopy. *Biotech Histochem* 1994; 69(4):219–234.
- 10 Weiglein A, Henry RW. Curing (hardening, polymerization) of the polymer – Biodur S10. *J Int Soc Plastination* 1993; 7(1):32–35.
- 11 Weber W, Henry RW. Sheet plastination of body slices – E12 technique, filling method. *J Int Soc Plastination* 1993; 7(1):16–22.
- 12 Weber W, Henry RW. Sheet plastination of the brain – P35 technique, filling method. *J Int Soc Plastination* 1992; 6(1):29–33.
- 13 O'Sullivan E, Mitchell BS. Plastination for gross anatomy teaching using low cost equipment. *Surg Radiol Anat* 1995; 17:277–281.
- 14 Tiedemann K, von Hagens G. The technique of heart plastination. *Anat Rec* 1982; 204:295–299.
- 15 Cooper MH, Kveton JF, Watson BJ. Preservation of the dissected and surgical anatomic detail in the human temporal bone. *Am J Otol* 1987; 8(1):18–22.
- 16 Pond KR, Holladay SD, Luginbuhl JM. Technical note: Preservation of tissues and gastrointestinal tract portions by plastic coating or plastination. *J Anim Sci* 1992; 70:1011–1014.

- 17 Lane A. Teaching sectional anatomy with sheet plastinated sections. 1st Interim Conf Plast, Knoxville, TN, USA, 1989. Abstract in *J Int Soc Plastination* 1989; 3(1):38.
- 18 de Boer-van Huizen RT, Cornelissen CJ, ten Donkelaar HT. Sheet plastination of the human head. *J Int Soc Plastination* 1992; 6(1):20–24.
- 19 Ulfing N, Wuttke M. Plastination of stained sections of the human brain. *Anat Anz* 1990; 170(5):309–312.
- 20 Purinton PT. Plastinated brains used with computer assisted learning modules for teaching veterinary neuroanatomy laboratories. *J Int Soc Plastination* 1991; 5(1):16–19.
- 21 Weiglein A. Plastinated brain-specimens in the anatomical curriculum at Graz University. *J Int Soc Plastination* 1993; 7(1):3–7.
- 22 Haffajee MR. Brain preparation to show fibre tracts and nuclei. *J Int Soc Plastination* 1996; 10(1):6–7.
- 23 Bickley HC, von Hagens G, Townsend FM. An improved method for the preservation of teaching specimens. *Arch Pathol Lab Med* 1981; 105:674–676.
- 24 Bickley HC. Plastination: A new technique for anatomic pathology and forensic science. *Pathology Update Series* 1984; 2(16):2–8.
- 25 Aufdemorte TB, Bickley HC, Krauskopf DR, Townsend FM. An epoxy resin and silicone impregnation technique for the preservation of oral pathology teaching specimens. *Oral Surg Oral Med Oral Pathol* 1985; 59:74–76.
- 26 Bickley HC, Walker AN, Jackson RL, Donner RS. Preservation of pathology specimens by silicone plastination: An innovative adjunct to pathology education. *Am J Clin Pathol* 1987; 88(2):220–223.
- 27 Rüschoff J, Thomas C. Plastination in der Pathologie. *Methodische und didaktische Erfahrungen mit der Biodur-S10-Standardtechnik*. *Pathologie* 1991; 12:35–39.
- 28 Fasel JHD. Use of plastinated specimens in surgical education and clinical practice. *Clin Anat* 1988; 1:197–203.
- 29 Resch KDM. Plastinated specimens for demonstration of microsurgical approaches to the base of the cranium. *J Int Soc Plastination* 1989; 3(1):29–33.
- 30 Graf J, Fromm B, Schneider U, Niethard FU. The application of the plastination method in experimental orthopaedic surgery. *J Int Soc Plastination* 1991; 5(1):20–22.
- 31 Fritsch H. Developmental changes in the retrorectal region of the human fetus. *Anat Embryol* 1988; 177:513–522.
- 32 Fritsch H. Staining of different tissues in thick epoxy resin-impregnated sections of human fetuses. *Stain Technol* 1989; 64(2):75–79.
- 33 Fritsch H. Topography and subdivision of the pelvic connective tissue in human fetuses and in the adult. *Surg Radiol Anat* 1994; 16:259–265.
- 34 Reidenbach MM, Schmidt HM. Topographical anatomy of the posterior elbow region during fetal development. *Ann Anat* 1994; 176:209–216.
- 35 Eckel HE, Sittel C, Walger M, Sprinzl G, Koebke J. Plastination: a new approach to morphological research and instruction with excised larynges. *Ann Otol Rhinol Laryngol* 1993; 660–665.
- 36 Brizzi E, De Caro R, Sgambati E, Todescan GC, Munari PF. The organization of subperitoneal connective tissue in the female pelvis. *Clin Exp Obst Gyn* 1994; XXI (4):253–258.
- 37 Fritsch H, Höttinger H. Tomographical anatomy of the pelvis, visceral pelvic connective tissue, and its compartments. *Clin Anat* 1995; 8:17–24.
- 38 Reidenbach MM. Topographical relations between the posterior cricothyroid ligament and the inferior laryngeal nerve. *Clin Anat* 1995; 8(5):327–333.
- 39 Reidenbach MM. Borders and topographic relationships of the paraglottic space. *Eur Arch Oto-Rhino-L* 1997; 254:193–195.
- 40 Guhr A, Müller A, Anton HW, von Hagens G, Bickley H. Complete examination of mastectomy specimens using sheet plastination with epoxy resin. *J Int Soc Plastination* 1987; 1(1):23–27.
- 41 Müller A, Guhr A, Leucht W, von Hagens G. Multicentricity of breast cancer. Results of a study using sheet plastination of mastectomy specimens. *J Int Soc Plastination* 1989; 3(1):8–14.
- 42 Graf J, Fromm B, Schneider U, Niethard FU. Early morphological changes in chondromalacia patellae in humans – demonstrated with the plastination method. *J Int Soc Plastination* 1992; 6(1):25–28.
- 43 Reidenbach MM. Normal topography of the conus elasticus. *Anatomical bases for the spread of laryngeal cancer*. *Surg Radiol Anat* 1995; 17(2):107–111.
- 44 Dilollo S, Menchi I, Brizzi E, Pacini P, Papucci A, Sgambati E, Gulisano M. The morphology of the prostatic capsule with particular regard to the posterosuperior region – An anatomical and clinical problem. *Surg Radiol Anat* 1997; 19(3):143–147.
- 45 Olry R, Motomiya K. Report on the 1996 Osaka plastination exhibition. *J Int Soc Plastination* 1997; 12(2):4–7.